

# Early Loading of Fluoridated Implants Placed in Fresh Extraction Sockets and Healed Bone: A 3- to 5-Year Clinical and Radiographic Follow-Up Study of 39 Consecutive Patients

Gert Oxby, DDS;\* Fredrik Oxby, DDS;\* Johan Oxby, BDS;\* Tomas Saltvik, DDS;\*  
Peter Nilsson, DDS, PhD\*\*

---

---

## ABSTRACT

*Background:* Immediate placement of implants in extraction sockets for early loading is an attractive treatment modality due to reduced treatment time. However, the outcome of fluoridated implants in this situation with regard to bone levels and health of soft tissues is not well documented.

*Purpose:* To evaluate the outcome of early loading of OsseoSpeed™ dental implants placed into fresh extraction sockets and healed bone in consecutive patients treated in a private clinic.

*Materials and Methods:* A total of 182 OsseoSpeed™ implants (Astra Tech Implant System, DENTSPLY Implants, Mölndal, Sweden), 72 in immediate extraction sockets and 110 in healed sites, were placed in 39 consecutive patients. The implants were loaded with permanent restorations within 60 days (average 31 days). Clinical and radiographic follow-up examinations were performed annually for at least 3 years (mean 55 months). An aesthetic index was used to evaluate the soft tissues adjacent to the prosthetic restorations.

*Results:* No implant was lost during the observation period, giving a survival rate of 100%. Bone level changes during the observation period were minimal, with a mean marginal bone loss of  $0.3 \pm 0.9$  mm around the delayed implants and a mean marginal bone gain of  $0.3 \pm 1.4$  mm around the immediate implants ( $p = .0036$ ). The frequency distribution of bone level revealed that 85% of implants placed in fresh extraction sockets and 84% of implants in healed bone did not show any loss of bone level during follow-up ( $p = \text{NS}$ ). Soft tissue complications were observed at two immediate implant sites in one patient. The remaining 180 implants received the highest aesthetic score. Moreover, no signs of peri-implant purulent infection or aggressive bone loss were found during the follow-up period.

*Conclusion:* Early loading of fluoridated implants with permanent constructions appears to be a viable therapy for implants placed immediately in extraction sites and in healed bone.

**KEY WORDS:** aesthetics, dental implants, early loading, extraction sockets, radiography

---

---

## INTRODUCTION

Immediate/early loading of implants in healed sites and extraction sockets is an attractive treatment modality in

implant patients with planned tooth extractions due to reduced treatment time. Several clinical studies on immediate loading of immediate implants have demonstrated successful results with regard to survival rate. In a recent systematic review, Del Fabbro and colleagues<sup>1</sup> concluded that immediate implants displayed “an excellent implant prognosis” but also that the conventional protocol still represents the “gold standard.” However, from a strictly scientific point of view, authors have also pointed out some shortcomings of the published literature. For instance, Lang and colleagues<sup>2</sup> concluded that more long-term studies are needed, and particularly with attention to aesthetics. Quirynen and colleagues<sup>3</sup> stated that the

---

\*Centre for Implant Dentistry, Tandvårdsgruppen, Lysekil, Sweden;  
†Department of Oral & Maxillofacial Surgery, The Institute for Post-graduate Dental Education, Jönköping, Sweden; ‡Department of Oral & Maxillofacial Surgery, Institute of Odontology, Sahlgrenska Academy, University of Gothenburg, Göteborg, Sweden

Corresponding Author: Dr. Gert Oxby, Klippgatan 6, SE-453 34 Lysekil, Sweden; e-mail: gert.oxby@tvg.nu

© 2014 Wiley Periodicals, Inc.

DOI 10.1111/cid.12210

majority of published studies did not report sufficiently on the presence of peri-implant bone defects at installation, the soft tissue status, sulcus depths, aesthetic outcomes, and the like. Chen and Buser<sup>4</sup> concluded that existing data are inconclusive due to the wide range of reported survival rates (65–100%) and that recession of the facial mucosa and papillae seems to be more common with immediate implants. Hence, more studies including parameters describing the morphology of the soft tissue before and after treatment are needed to better evaluate the feasibility of this treatment modality.

Another factor of importance for the clinical outcome is the type of implant used. The OsseoSpeed™ implant surface is a further development of the TiOblast™ implant surface. The surface is fluoride-modified; evidence of its bioactive potential includes both biomechanical and histomorphometric data.<sup>5</sup> Ellingsen and colleagues<sup>6</sup> reported that a fluoride-modified titanium surface demonstrates firmer bone anchorage than an unmodified control surface. These results agree with results from other animal studies. Berglundh and colleagues<sup>7</sup> and Abrahamson and colleagues<sup>8</sup> reported that fluoridated implants achieve greater bone integration than their unmodified predecessors. Mertens and Steveling<sup>9</sup> and Schliephake and colleagues<sup>10</sup> showed in two different 5-year prospective clinical studies that early and immediate loading of fluoridated implants resulted in a low degree of marginal bone reduction and high implant survival rates.

The objective of the present article was to report the clinical and radiographic medium- to long-term results of fluoridated implants placed into both fresh extraction sockets and healed bone for early loading with final prosthetic constructions.

## MATERIALS AND METHODS

### Patients and Ethical Considerations

Fifty-two consecutive patients treated between January 2004 and April 2006 with dental implants in one clinic

were initially reviewed for the study. The inclusion criteria were (i) treatment with OsseoSpeed™ implants (Astra Tech Implant System, DENTSPLY Implants, Mölndal, Sweden), (ii) full surgical and prosthetic treatment in the clinic, and (iii) loading with a permanent prosthetic construction less than 60 days after surgery (early loading).<sup>11</sup> Thirteen patients did not fulfill the inclusion criteria and were excluded. Thirty-nine patients were included, and in 24 of these, one or more implants had been placed in healed sites as well as into extraction sockets immediately after tooth removal in healed sites (Table 1). All implants in the remaining 14 patients were placed in healed bone (Figure 1). The radiographic examination prior to treatment included intraoral and panoramic radiographs and, if required, tomography.

None of the participants suffered from any severe systemic disease. There was no sign of ongoing infection around any of the teeth planned for extraction. Smoking was not a cause for exclusion, though only one of the patients was a heavy smoker (more than 40 cigarettes a day).

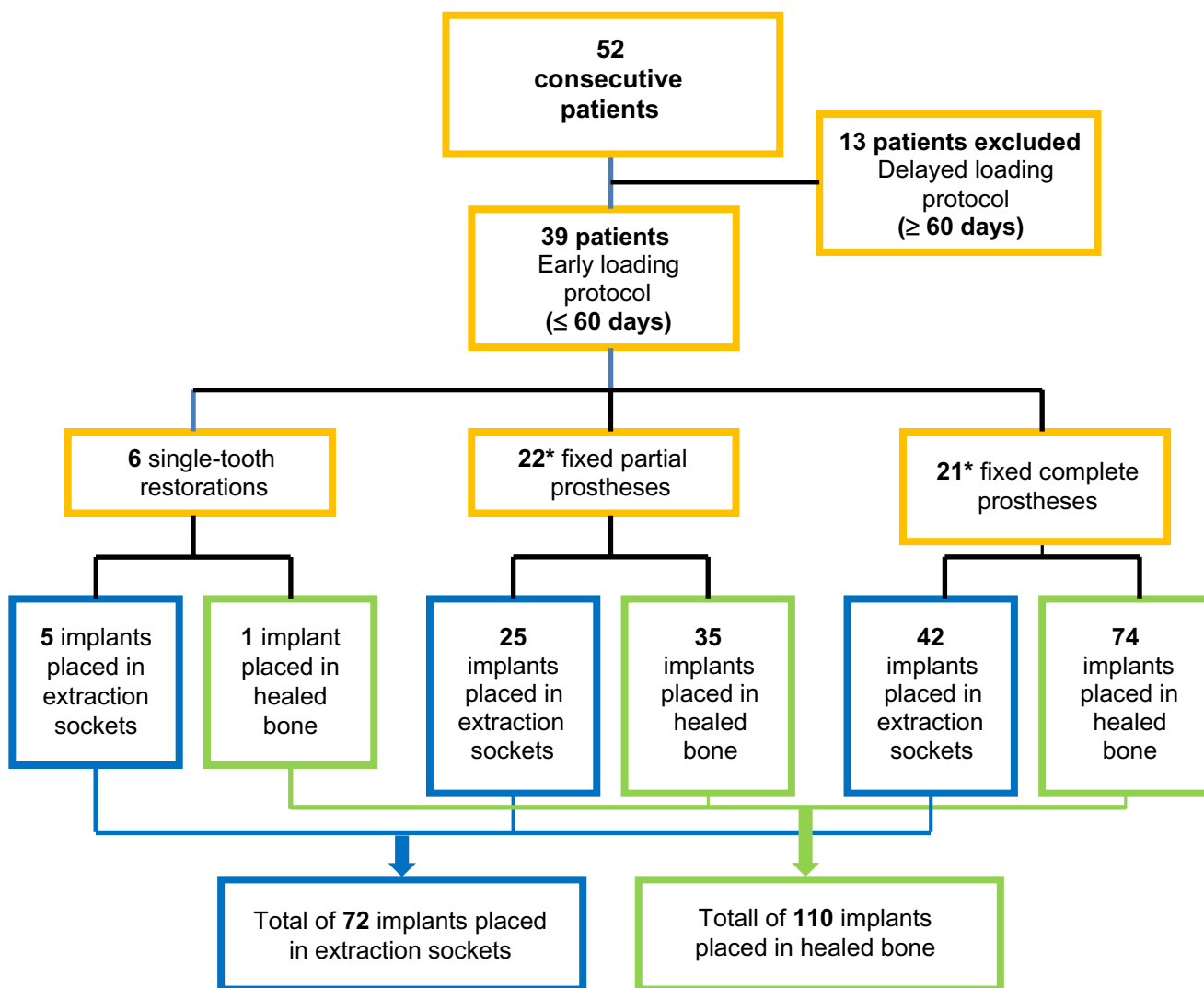
Prior to commencement of the study, the Ethical Review Board at the University of Gothenburg, Sweden, was consulted. Given the nature of the study (consecutive follow-up), the committee advised that no ethical approval was necessary. All patients in the study provided informed consent before being treated, and all aspects of the Declaration of Helsinki were respected. Before the individual therapy was definitively determined, each of the patients was informed about the treatment alternatives. No patients declined to participate in the study.

### Surgical Protocol

The surgical procedures were carried out under local anesthesia and with antibiotics (clindamycin 600 mg; Dalacin, Pfizer AB, Sollentuna, Sweden) from the day before surgery and for 9 days postoperatively.

**TABLE 1** Age and Gender Distribution of the Presented Group of Patients

	Age Range (Years)				Total	Mean (Years)
	20–60	61–70	71–80	>80		
Female	3	5	7	2	17	68
Male	4	7	7	4	22	68
Total	7	12	14	6	39	68

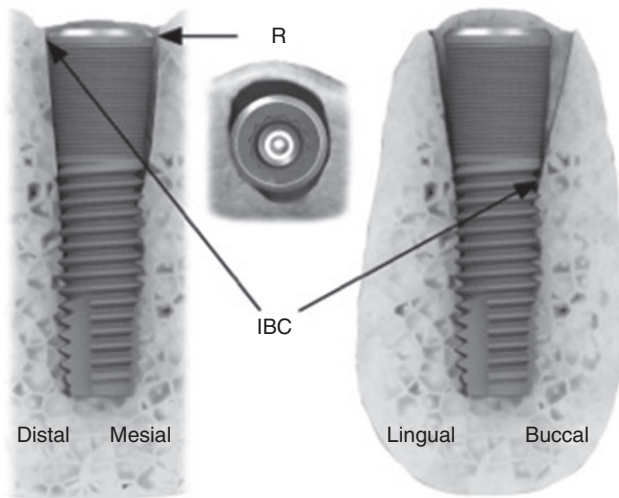


**Figure 1** Flowchart describing the number of patients, distribution and types of restorations, and distribution of implants placed in fresh extraction sockets and in healed bone. \*Some patients were treated with more than one type of restoration.

Healed sites were exposed via crestal incisions and mucoperiosteal flaps. Implant site preparation followed the protocol given by the manufacturer (DENTSPLY). The fixture sites were prepared by a series of drilling steps. The diameter of the final twist drill was selected to fit the self-tapping fixture diameter, and there was also a choice to accommodate different bone qualities. To optimize the fixture-bone relationship and to give good primary stability for the fixture without creating pressure in the bone, two choices of final twist drill diameters were available for each fixture diameter. Implants were submerged to the level of the bone crest. In thin maxillary ridges, implants were installed to the palatal side of the ridges in order to avoid exposed threads on the buccal side. Some of the implants instead had exposed palatal threads.

Teeth planned for extraction were removed using periostomes (Table 2). Great attention was paid to preserving the often very thin buccal compact bone wall. The sockets were thoroughly debrided, and mucoperiosteal buccal flaps were elevated. Immediate implants

TABLE 2 Reason for Extraction	
Extraction Indication	n Teeth
Technical	24
Decayed	18
Periodontal	22
Fractured	7
Ankylosis	1
Total	72



**Figure 2** Left: Frontal cross-section of OsseoSpeed™ implant placed in an extraction socket. Right: Sagittal cross-section. R = reference point (lateral rim of implant platform); IBC = most apical implant-bone contact point.

were inserted to a depth such that the implant platform was approximately 1 mm below the buccal bone margin of the sockets. It was generally possible to achieve some contact between the implant and the mesial and/or distal bone in the upper part of the extraction sockets. The corresponding buccal and lingual contacts generally were located significantly deeper (Figure 2).

Bone harvested during drilling (BoneTrap™, DENTSPLY) was mixed with roughly 25% PerioGlas™ (NovaBone® Products LLC, Alachua, FL, USA) and used to fill any voids. A total of 182 fluoridated implants were placed in the 39 patients, with 72 (40%) placed immediately after tooth extraction and 110 (60%) placed in healed bone (Table 3). A suitable healing abutment was connected to each implant. The margins of the soft

tissue around the extraction sockets were adapted and sutured with resorbable coated Vicryl® (Ethicon, Inc., Somerville, NJ, USA) to reduce the open extraction wound. However, no attempts were made to mobilize the buccal mucosa to completely cover the wound.

**Restorative Protocol**

Impressions were taken 10 to 14 days after surgery. The fixed partial prostheses (FPPs) and fixed complete prostheses (FCPs) were fabricated according to the Cresco Precision™ method (DENTSPLY)<sup>12,13</sup> and were screw-retained. The single-tooth (ST) implants were restored by screw-retained metal-ceramic crowns.<sup>14</sup> All ST crowns had adjacent teeth.

Forty-nine permanent fixed restorations were delivered and loaded within 53 days (range 14–53 days, average 31 days) and thus fulfilled the criterion for early loading.<sup>11</sup> Eight of the 39 patients received two restorations, while one patient got three (Figure 3, A–D).

**Clinical Follow-Up**

The patients were recalled annually for clinical and radiographic examinations during an observation time from 36 to 63 months (mean 55 months) (Table 4). The clinical examinations included evaluation of stability of constructions, oral hygiene, and health of peri-implant soft tissues using probes. Moreover, clinical photographs were taken at each follow-up visit to enable evaluation of the aesthetic outcomes over time. Based on the clinical photographs, an index was created to review the aesthetic outcomes (Table 5). The index included three possible scores: 1 (intact buccal gingiva), 2 (exposed abutment), and 3 (exposed abutment and implant neck) (Figure 4, A–C).

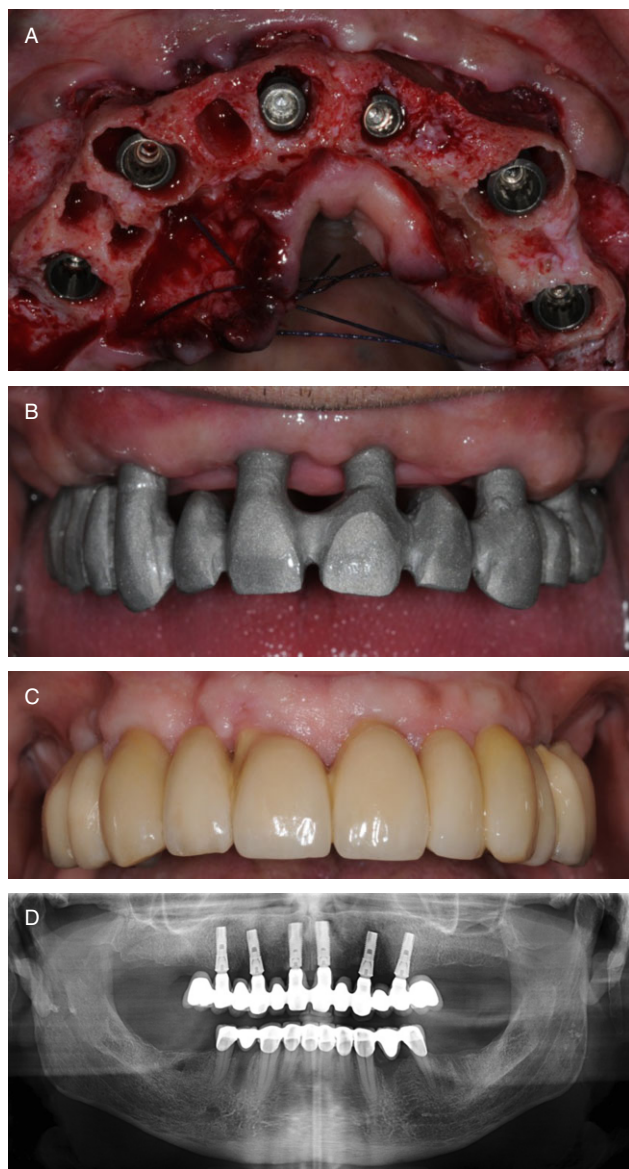
TABLE 3 Distribution of Implants, by Length and Diameter, Placed in Extraction Sockets and Healed Bone											
Length (mm)	Extraction Sockets					Healed Bone					All Implants
	Diameter (mm)					Diameter (mm)					
	3.5	4.0	4.5	5.0	Total	3.5	4.0	4.5	5.0	Total	
11	0	1	0	0	1	4	8	2	4	18	19
13	3	2	3	3	11	10	7	4	6	27	38
15	7	9	0	17	33	35	12	4	2	53	86
17	2	6	6	8	22	2	2	2	5	11	33
19	1	0	0	4	5	0	0	0	1	1	6
Total	13	18	9	32	72	51	29	12	18	110	182

## Radiographic Follow-Up

A conventional radiographic technique was used for the baseline examinations at delivery of the restorations, while a digital technique was used for the follow-up examinations. A long-cone technique was used for the periapical radiographs, and special efforts were made to obtain a perpendicular projection toward the implant. Measurements from the radiographs taken at baseline

**TABLE 4** Distribution of Follow-Up Time for Patients and Implants

	Follow-Up Time (Months)			Total
	36–48	49–60	>60	
Mean follow-up (months) time	39	56	63	54
Number of patients	6	25	8	39
Number of implants	38	114	30	182



**Figure 3** A, Clinical case, fixed complete prosthesis (FCP), upper jaw. Implants in tooth sites 15, 13, 11, 23, and 25 were placed in fresh extraction sockets; that in 21 was placed in a healed bone. B, Try-in of cobalt chromium framework, FCP, upper jaw, 39 days after implant installation. C, FCP, heavy smoker after 7 years. Early loading 21 days post-surgery. Aesthetic index scored as 1 (intact buccal gingivag). D, Panoramic image 30 months post-loading, FCP.

and at the final examinations were used for the presentation of the radiographic results. All measurements were carried out by an independent radiologist using paired views. The outer rim of the implant platform was used as the reference point for the measurements (Figure 2). The bone level was defined and recorded as the distance from the reference point to the proximal implant-bone contact level. A magnifying eyepiece loupe ( $\times 7$ ) was used for the measurements, which were recorded to the nearest 0.1 mm. The error of the radiographic assessment was determined using double recordings at one randomly selected implant from each patient and found to be  $0.04 \pm 0.33$  mm.

## Statistics

The Wilcoxon rank-sum test was used to compare implants in healed sites and extraction sockets with regard to radiographic marginal bone levels and bone loss. The Wilcoxon signed-rank test was used to compare changes within each group. As there was a skewed distribution of implants placed in extraction sockets and healed bone in individual patients, only the groups were compared, that is, an intraindividual comparison was not carried out. The mean of the recordings from each mesial and distal implant site was the unit used for the statistical analysis. All  $p$  values were two-sided, and  $p < .05$  was considered statistical significance.

## RESULTS

### Clinical Follow-Up

During the course of the study, three of the 39 patients died from unrelated causes, and one patient relocated and could not undergo the final examination. However, all 39 patients were followed for at least 36 months.

No implants were lost during the follow-up during the 36- to 63-month observation period, giving a

TABLE 5 Aesthetic Index Distribution

	Aesthetic Index Score		
	1 (Intact Buccal Gingiva)	2 (Exposed Abutment)	3 (Exposed Abutment and Implant Neck)
Implants ( <i>n</i> )	180	0	2

survival rate of 100% for both implants in healed sites and those in extraction sockets. There were no signs of peri-implant purulent infection with aggressive marginal bone loss during the follow-up period.

The aesthetic evaluation showed good soft tissue preservation over time. Soft tissue complications (exposed abutments and implant necks) were only observed at 2 of the implants, which were scored as 3 on the aesthetic index (Figure 5). The remaining 180 implants were evaluated as 1 on the aesthetic index (intact buccal gingiva) (Table 5).

#### Radiographic Follow-Up

The average bone level at baseline was significantly lower ( $p = .0002$ ) at implants in fresh extraction sockets ( $-1.0 \pm 1.3$  mm) compared with implants in healed sites ( $-0.3 \pm 0.6$  mm). The corresponding values after 3 to 5 years of function were identical ( $-0.6 \pm 0.7$ ) and thus not significantly different (Table 6).

The change of bone level from baseline to the 3- to 5-year visit was significantly different ( $p = .0036$ ). An average bone loss of  $0.3 \pm 0.9$  mm was seen at implants placed in healed bone, and a bone level gain of  $0.3 \pm 1.4$  mm was seen for the implants in fresh extraction sockets (Table 6).

The frequency distribution of bone level revealed that 85% of implants placed in fresh extraction sockets

and 84% of implants in healed bone did not show any loss of bone level during follow-up ( $p = \text{NS}$ ) (Table 7). The proportions of implants with bone levels from 0 to 0.9 mm from the reference points at the 3- to 5-year follow-up were 72% and 78% in implants placed in fresh extraction sockets and those placed in healed bone, respectively ( $p = \text{NS}$ ).

#### DISCUSSION

One definition of early loading of dental implants is loading from 1 week to 2 months subsequent to implant placement<sup>11</sup>; this is a wide range. The primary stability due to mechanical press-fit at surgery is estimated to decrease gradually during the first 3 postsurgical weeks, after which secondary stability due to formation of direct bone-implant contacts starts to develop.<sup>15</sup> Most of the implants in the present study were splinted and loaded during the early osseointegration phase (at 31 days after implant placement, on average). Early splinting of the newly inserted implants by a well-dimensioned, rigid, permanent, and passively fitting restoration (single-tooth implants excluded) was therefore considered important. Hypothetically, it can be assumed that good fit of the superstructure to the implants reduces the risk for transmission of deteriorating stresses and strains to the bone-implant interface during the early critical phase of the healing process. The

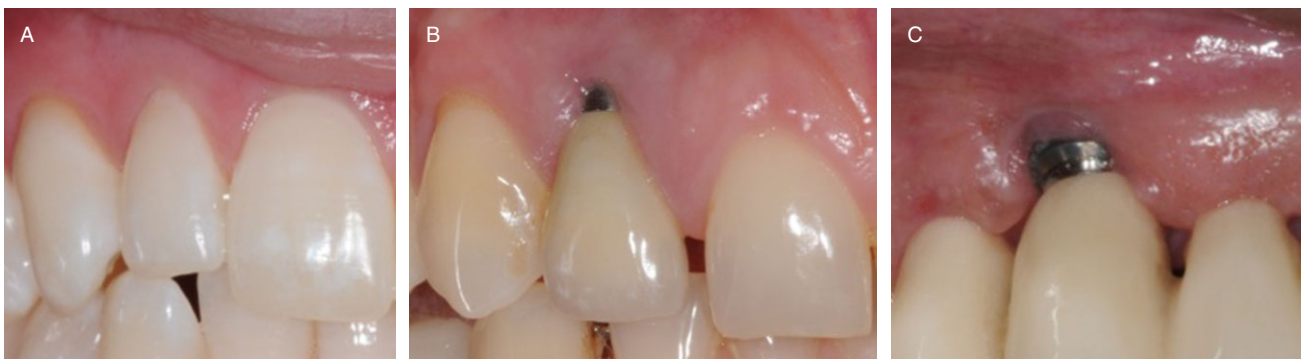
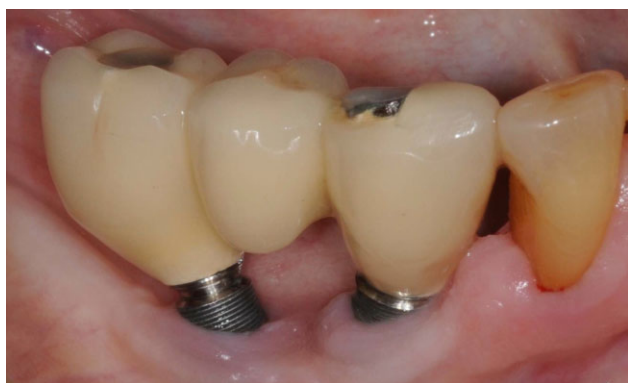
Figure 4 A, Intact buccal gingiva. B, Exposed abutment. C, Exposed abutment and implant neck.



**Figure 5** Male, age 75, 59 months post-loading. Implant in site 45 was placed in healed bone and that in 43 was placed in a fresh extraction socket. Both implants were scored as 3 on the aesthetic index (exposed abutments and implant necks).

early splinting of the implants in the present study using rigid and precisely fitting superstructures may have been a significant factor contributing to the favorable treatment results. All frameworks were fabricated according to the Cresco Precision method,<sup>12,13</sup> which has been shown to lead to an optimal fit between the implants and framework.<sup>16,17</sup> The alternative of using less rigid

temporary acrylic constructions may pose increased risk of micromotion, fracture, and overloading due to misfit. All restorations, except for single-tooth implants, were screw-retained, which made it possible to remove the restorations to check implant stability and reline/rebase the bridge to compensate for soft tissue shrinkage.

An extraction socket is normally asymmetric, with a wider distance between the buccal and lingual walls than between the mesial and distal walls. After immediate implant placement, the IBC is normally located higher mesially and distally than buccally and lingually. According to Botticelli and colleagues,<sup>18</sup> the buccal and lingual defects are approximately two to three times deeper than the proximal defects. As an implant is radiographically dense, a conventional planar image gives very little information about the buccal and lingual bone-implant relationship. It can therefore be assumed that the baseline measurements of mesial and distal bone levels in extraction sockets were underestimated. As a consequence, the bone-gain values presented for the immediate implants were probably greater than given by the measurements. The shortcomings of conventional radiographs for

**TABLE 6** Distance between the Reference Point and the Marginal Bone Level in Extraction Sockets and Healed Bone

	Distance from Reference Point (mm), Mean $\pm$ SD		Marginal Bone Level Change (mm) <sup>‡</sup>
	At Baseline <sup>*</sup>	At Follow-Up <sup>†</sup>	
Healed bone ( $n = 110$ )	0.34 $\pm$ 0.62	0.63 $\pm$ 0.74	-0.28 $\pm$ 0.88 ( $p < .0001$ )
Extraction sockets ( $n = 72$ )	0.96 $\pm$ 1.32	0.63 $\pm$ 0.65	+0.32 $\pm$ 1.44 ( $p < .2772$ )
Difference between groups ( $p$ )	.0002	.7119	.0036

\*Delivery of prostheses.

<sup>†</sup>Last follow-up examination.

<sup>‡</sup>Minus sign denotes bone loss; plus sign denotes bone gain.

**TABLE 7** Frequency Distribution of Bone Levels at Baseline and at the 3- to 5-Year Follow-Up

Bone Level at Baseline (mm)	Implants Placed in Extraction Sockets ( $n$ )					Implants Placed in Healed Bone ( $n$ )				
	Bone Level at Follow-Up (mm)				Total	Bone Level at Follow-Up (mm)				Total
	0.0–0.9	1.0–1.9	2.0–2.9	$\geq 3.0$		0.0–0.9	1.0–1.9	2.0–2.9	$\geq 3.0$	
0.0–0.9	36	10	0	1	47	78	10	4	2	94
1.0–1.9	8	3	0	0	11	6	6	2	0	14
2.0–2.9	3	3	1	0	7	0	0	0	0	0
$\geq 3.0$	5	2	0	0	7	2	0	0	0	2
Total	52	18	1	1	72	86	16	6	2	110

ascertaining the bone-contact levels around implants – particularly immediate implants – make the evidence level of the radiographic method low and less confirmative. The validity of proximal measurements has also been questioned, especially if there is not a strict parallelism between the implant axes and film plane and if the beam projection is not orthoradial and perpendicular to the implant.<sup>19</sup> The use of a mixture of harvested bone and Perioglas™ in the void between the implant and socket walls is another radiographic uncertainty factor, as it may mask the true IBC. Despite these considerations, there are still reasons from a clinical point of view to consider the radiographic images sufficiently adequate for identifying changes of the proximal marginal bone levels. Moreover, radiographic observations can be combined with probing of the peri-implant sulcus depths. The cone-beam computed tomography technique<sup>20</sup> appears to be a promising and significantly more accurate method for future studies of bone and soft tissue changes around implants placed in extraction sockets.

The conventional baseline for radiographic measurements reported in the implant literature has been the initiation of prosthetic loading – usually 3 to 6 months after implant placement.<sup>21–23</sup> Bone loss on the order of 1 mm between surgery and the time for conventional loading has been frequently reported and is widely regarded as acceptable.<sup>24</sup> In the present study (average 31 days), the radiographic baseline measurements were assessed from radiographs taken much earlier. In spite of this, about 85% of the implants in healed sites showed less than 1 mm of bone loss during the 3- to 5-year observation time (mean loss  $0.3 \pm 0.9$  mm). This is in parity with the most favorable results reported for conventionally loaded, moderately rough-surfaced implants. Wennström and colleagues<sup>25</sup> reported a mean marginal bone loss of 0.1 mm (SD 1.00) over a 5-year period for 45 conventionally loaded AstraTech TiOblast ST implants. The measurements for the immediate implants after 3 to 5 years in this study demonstrated a mean bone gain of  $0.3 \text{ mm} \pm 1.4$ , and as discussed above, these numbers are probably significantly underestimated. More interesting and notable, however, is that the marginal bone level did not significantly differ between the immediate implants and implants in healed sites at the end of the observation time, that is, bone gain at the implants in extraction sites resulted in similar bone levels as for implants in healed sites.

Based on results from reentry studies, there was reason to expect that the marginal bone level measurements might demonstrate bone loss for most of the immediate implants due to an incomplete bone fill of the buccal and lingual voids<sup>26</sup> and a concomitant circumferential bone remodeling in order to level out discrepancies of the bone margins.<sup>27</sup> However, less than 6% of the sites exhibited evident (more than 1 mm) loss of proximal bone. This low incidence was interpreted as an indication of successful bone fill even buccally and lingually for the majority of the implants. These radiographic findings are in line with results reported from experimental studies on fluoridated implants<sup>7,8</sup> and clinical reentry studies demonstrating complete bone fill of defects around implants placed in extraction sockets.<sup>17,26,28,29</sup> The results also agree with results reported from similar clinical studies.<sup>30,31</sup> In a prospective randomized controlled clinical trial, Sanz and colleagues placed 99 OsseoSpeed implants into fresh extraction sockets in maxillae in 93 patients, with the aim of evaluating bone preservation.<sup>32</sup> After 16 weeks, a reentry surgery was performed, and measurements of the bone were recorded. The authors concluded that implant placement into extraction sockets results in significant bone reduction of the alveolar ridge. However, all implants in that study were placed level with the buccal bone margin and were unloaded during the entire healing period, which may have influenced the results.

It is generally assumed that a moderately roughened implant surface ( $S_a$  1.0–2.0  $\mu\text{m}$ ) results in a stronger bone tissue response than turned and very rough surfaces.<sup>5,17,33</sup> The implant surface in the present study was moderately rough up to the lateral border of the platform. It has been suggested that, when placed in a socket level with or below the bone margin, bone healing can result in complete integration of the moderately rough surface up to the implant platform level.<sup>30,34</sup> The favorable results from this study indicate successful bone apposition to the implants in extraction sockets. In addition to the surface topography, the fluoridated implant surface seems to possess properties that result in further improved bony anchorage.<sup>5–10</sup> On the other hand, in a histological study in dogs, de Sanctis and colleagues failed to demonstrate differences in the bone-healing pattern after 6 weeks when placing four different implant systems (including fluoridated implants) in fresh extraction sockets.<sup>35</sup>



In a review on the clinical and aesthetic outcome of implants placed in post extraction sites, the authors concluded that this type of treatment is successful.<sup>4</sup> The majority of the studies reported survival rates of more than 95%, with survival rates being similar for immediate and early placement. Risk indicators included a thin tissue biotype, facial malpositioning of the implant, and thin or damaged facial bone walls. From a clinical reentry study Chen and colleagues concluded that marginal bone defects adjacent to implants placed in fresh extraction sockets heal predictably, whether or not bone grafts and/or barrier membranes are used.<sup>26</sup> The risk of adverse aesthetic outcomes reinforces the recommendation to carefully consider the risk for aesthetic complications following immediate implant therapy.

For this study, a simple aesthetic index was created to evaluate the aesthetic outcomes over time (1, intact buccal gingival; 2, exposed abutment; 3, exposed abutment and implant neck). Recession of the soft tissue surrounding the implant superstructure is a well-known cause of aesthetic failure. The authors assumed that if the buccal gingiva was intact, there was reason to assume that the surrounding bone also was intact and would provide sufficient long-term gingival support for acceptable aesthetics. This might support the interpretation of the radiographic findings as successful bone fill of the peri-implant defects discussed earlier.

## CONCLUSION

Early loading of fluoridated implants with permanent constructions appears to be a viable therapy for implants placed immediately in extraction sites and in healed bone.

## REFERENCES

1. Del Fabbro M, Wallace SS, Testori T. Long-term implant survival in the grafted maxillary sinus: a systematic review. *Int J Periodontics Restorative Dent* 2013; 33:773–783. doi: 10.11607/prd.1288.
2. Lang NP, Pun L, Lau KY, Li KY, Wong MC. A systematic review on survival and success rates of implants placed into fresh extraction sockets after at least 1 year. *Clin Oral Implants Res* 2012; 23(Suppl 5):39–66. doi: 10.1111/j.1600-0501.2011.02372.x.
3. Quirynen M, Van Assche N, Botticelli D, Berglundh T. How does the timing of implant placement to extraction affect outcome? *Int J Oral Maxillofac Implants* 2007; 22(Suppl ):203–220.
4. Chen ST, Buser D. Clinical and esthetic outcomes of implants placed in postextraction sites. *Int J Oral Maxillofac Implants* 2009; 24(Suppl):186–217.
5. Wennerberg A, Albrektsson T. Implant surfaces beyond micron roughness. Experimental and clinical knowledge of surface topography and surface chemistry. *Appl Osseointegration Res* 2006; 5:40–44.
6. Ellingsen JE, Johansson CB, Wennerberg A, Holmén A. Improved retention and bone-to-implant contact with fluoride-modified titanium implants. *Int J Oral Maxillofac Implants* 2004; 19:659–666.
7. Berglundh T, Abrahamsson I, Albouy JP, Lindhe J. Bone healing at implants with a fluoride-modified surface: an experimental study in dogs. *Clin Oral Implants Res* 2007; 18:147–152.
8. Abrahamsson I, Albouy JP, Berglundh T. Healing at fluoride-modified implants placed in wide marginal defects: an experimental study in the dogs. *Clin Oral Implants Res* 2008; 19:153–159.
9. Mertens C, Steveling HG. Early and immediate loading of titanium implants with fluoride-modified surfaces: results of 5-year prospective study. *Clin Oral Implants Res* 2011; 22:1354–1360.
10. Schliephake H, Rödiger M, Phillips K, McGlumphy EA, Chacon GE, Larsen P. Early loading of surface modified implants in the posterior mandible – 5 year results of an open prospective non-controlled study. *J Clin Periodontol* 2012; 39:188–195.
11. Weber HP, Morton D, Gallucci GO, Rocuzzo M, Cordaro L, Grütter L. Consensus statements and recommended clinical procedures regarding loading protocols. *Int J Oral Maxillofac Implants* 2009; 24(Suppl):180–183.
12. Helldén LB, Ericson G, Olsson CO. The Cresco bridge and implant concept: presentation of a technology for fabrication of abutment-free, passively fitting superstructures. *Int J Periodontics Restorative Dent* 2005; 25:89–94.
13. Oxby G, Lindqvist J, Nilsson P. Early loading of Astra Tech OsseoSpeed™ implants placed in thin alveolar ridges and fresh extraction sockets. *Applied Osseointegration Res* 2006; 5:68–72.
14. Oxby G, Bengtsson J, Busch S, Hedqvist L, Lindqvist J, Moberg P. An alternative method for the fabrication of customised abutments for single tooth replacements. A clinical follow-up after 18 months. *Swed Dent J* 2004; 28:21–27.
15. Raghavendra S, Wood MC, Taylor TD. Early wound healing around endosseous implants: a review of the literature. *Int J Oral Maxillofac Implants* 2005; 20:425–431.
16. Helldén LB, Dérand T. Description and evaluation of a simplified method to achieve passive fit between cast titanium frameworks and implants. *Int J Oral Maxillofac Implants* 1998; 13:190–196.
17. Torsello F, Mirisola di Torresanto V, Ercoli C, Cordaro L. Evaluation of the marginal precision of one-piece complete

- arch titanium frameworks fabricated using five different methods for implant-supported restorations. *Clin Oral Implants Res* 2008; 19:772–779.
18. Botticelli D, Berglundh T, Lindhe J. Hard-tissue alterations following immediate implant placement in extraction sites. *J Clin Periodontol* 2004; 31:820–828.
  19. Sewerin IBP. Errors in radiographic assessment of marginal bone height around osseointegrated implants. *Scand J Dent Res* 1990; 98:428–433.
  20. Miyamoto Y, Obama T. Dental cone beam computed tomography analyses of postoperative labial bone thickness in maxillary anterior implants: comparing immediate and delayed implant placement. *Int J Periodontics Restorative Dent* 2011; 31:215–225.
  21. Albrektsson T, Zarb G, Worthington P, Eriksson AR. The long-term efficacy of currently used dental implants: a review and proposed criteria of success. *Int J Oral Maxillofac Implants* 1986; 1:11–25.
  22. Albrektsson T, Zarb GA. Current interpretations of the osseointegrated response: clinical significance. *Int J Prosthodont* 1993; 6:95–105.
  23. Albrektsson T, Isidor F. Consensus report of session IV. In: Lang NP, Karring T, eds. *Proceedings of the First European Workshop on Periodontology*. London: Quintessence, 1994:365–369.
  24. Åstrand P, Engquist B, Dahlgren S, Gröndahl K, Engquist E, Feldmann H. Astra Tech and Brånemark system implants: a 5-year prospective study of marginal bone reactions. *Clin Oral Implants Res* 2004; 15:413–420.
  25. Wennström JL, Ekstubb A, Gröndahl K, Karlsson S, Lindhe J. Implant-supported single-tooth restorations: a 5-year prospective study. *J Clin Periodontol* 2005; 32:567–574.
  26. Chen ST, Darby IB, Reynolds EC. A prospective clinical study of non-submerged immediate implants: clinical outcomes and esthetic results. *Clin Oral Implants Res* 2007; 18:552–562.
  27. Carmagnola D, Araújo M, Berglundh T, Albrektsson T, Lindhe J. Bone tissue reaction around implants placed in a compromised jaw. *J Clin Periodontol* 1999; 26:629–635.
  28. Covani U, Barone A, Cornelini R, Crespi R. Soft tissue healing around implants placed immediately after tooth extraction without incision: a clinical report. *Int J Oral Maxillofac Implants* 2004; 19:549–553.
  29. Ferrus J, Cecchinato D, Pjetursson EB, Lang NP, Sanz M, Lindhe J. Factors influencing ridge alterations following immediate implant placement into extraction sockets. *Clin Oral Implants Res* 2010; 21:22–29.
  30. Jaffin RA, Kolesar M, Kumar A, Ishikawa S, Fiorellini J. The radiographic bone loss pattern adjacent to immediately placed, immediately loaded implants. *Int J Oral Maxillofac Implants* 2007; 22:187–194.
  31. Nordin T, Graf J, Frykholm A, Helldén L. Early functional loading of sand-blasted and acid-etched (SLA) Straumann implants following immediate placement in maxillary extraction sockets. Clinical and radiographic result. *Clin Oral Implants Res* 2007; 18:441–451.
  32. Sanz M, Cecchinato D, Ferrus J, Pjetursson EB, Lang NP, Lindhe J. A prospective, randomized-controlled clinical trial to evaluate bone preservation using implants with different geometry placed into extraction sockets in the maxilla. *Clin Oral Implants Res* 2010; 21:13–21.
  33. Abrahamsson I, Berglundh T, Linder E, Lang NP, Lindhe J. Early bone formation adjacent to rough and turned endosseous implant surfaces. An experimental study in the dog. *Clin Oral Implants Res* 2004; 15:381–392.
  34. Hämmerle CHF, Brägger U, Bürgin W, Lang NP. The effect of subcrestal placement of the polished surface of ITI® implants on marginal soft and hard tissues. *Clin Oral Implants Res* 1996; 7:111–119.
  35. de Sanctis M, Vignoletti F, Discepoli N, Zucchelli G, Sanz M. Immediate implants at fresh extraction sockets: bone healing in four different implant systems. *J Clin Periodontol* 2009; 36:705–711.